



PATIENT

Kirby Tissot

PRESENTING CLINICAL SIGNS

History: Grade 3/6 heart murmur. History of spinal compression and chronic cervical disc disease. Assess prior to dental.

SPECIES

Canine

ELECTROCARDIOGRAPHIC FINDINGS

A six lead ECG is available at 25mm/s; 0mm/mV. The average heart rate is 120bpm (range 68-150bpm). The rhythm is sinus in origin, with a p for every QRS complex and vice versa. The P wave morphology is positive with a normal dimension. Normal PR. The QRS morphology is positive with normal dimension. MEA is normal. No ectopic beats, pauses or dysrhythmias observed.

BREED

Beagle

ECG diagnosis: Normal sinus rhythm with respiratory variation.

SEX

Male Intact

ECHOCARDIOGRAM FINDINGS

2D, m-mode, color flow and doppler imaging is available. Mild diffuse thickening of mitral valve leaflets with mild prolapse into the left atrial lumen. Mild eccentric mitral regurgitation with no left atrial dilation. Normal MR velocity. Normal LV diameter with adequate myocardial function. The tricuspid valve appears normal with trace tricuspid regurgitation. Normal right atrial and ventricular diameter and morphology indicating no overt evidence of pulmonary arterial hypertension. The pulmonic and aortic valves are normal in morphology and mobility. Normal pulmonic and aortic outflow velocities with laminar flow. No obvious aortic or pulmonic insufficiency. No pericardial or pleural effusion noted. No obvious cardiac masses.

AGE

13.1 years

WEIGHT

32.4lbs

CARDIAC CHART

INTERPRETED BY

Maggie Machen Lamy,
DVM, DACVIM
(Cardiology)

| CANINE CARDIAC PARAMETERS | MR VMAX (m/s) | TR VMAX (m/s) | LA/AO (Boon method) | LA/AO (Heart Base; Swe) | FS (%) | EF (%) | EPSS (cm) |
|--|---------------|---------------|---------------------|-------------------------|---------------------------------|--|--|
| NORMAL PARAMETER | 4.5-5.5 | <2.7 | 1.3 | <1.6 | 28-40 | 40-100 | <0.6 |
| PATIENT | 5.8 | NM | NM | 1.2 | 32 | 60 | 0.3 |
| CANINE CARDIAC PARAMETERS | HR (BPM) | AV VMAX (m/s) | PV MAX (m/s) | BODY WEIGHT (kg) | LA 2D short axis Base view (cm) | LVIDd Avg; 2D and m-mode short axis (cm) | LVIDs Avg; 2D and m-mode short axis (cm) |
| NORMAL PARAMETER | 50-100 | 0.7-1.7 | 0.7-1.6 | BELOW | BELOW | BELOW | BELOW |
| PATIENT | NM | 1.0 | NM | 14.7 | 2.1 | 2.8 | 1.9 |
| *Normal chamber parameters expressed as a mean value (SD) | | | | | | | |
| BODY WEIGHT DEPENDENT PARAMETERS | | | | | | | |
| *Note: All measurements based upon multi-modal images and methods. An average value is reported. | | | | | | | |
| Adapted from June Boon, Veterinary Echocardiography, 1998 | | | | | | | |
| Rishniw M and Hollis NE, J Vet Intern Med 2000; 14:429-435 | | | | | | | |
| Hansson et al, Vet Rad and Ultrasound 2002 | | | | | | | |
| Bonagura et al. Echocardiography: principles of interpretation, Vet Clin North Am 15:1177, 1995 | | | | | | | |
| | 5 | 1.40 (4.5) | 2.74 (5.2) | 1.60 (4.7) | | | |
| | 10 | 1.50 (3.8) | 3.27 (3.5) | 2.06 (3.1) | | | |
| | 15 | 1.83 (2.0) | 3.71 (2.4) | 2.43 (2.1) | | | |
| | 20 | 2.02 (1.9) | 4.14 (2.2) | 2.80 (2.0) | | | |
| | 25 | 2.18 (2.4) | 4.48 (2.9) | 3.10 (2.5) | | | |
| | 30 | 2.33 (3.3) | 4.83 (3.9) | 3.39 (3.4) | | | |
| | 35 | 2.48 (4.3) | 5.17 (5.0) | 3.69 (4.5) | | | |
| | 40 | 2.62 (5.2) | 5.48 (6.1) | 3.96 (5.4) | | | |
| | 50 | 2.88 (7.1) | 6.07 (8.3) | 4.46 (7.4) | | | |

IMAGING PERFORMED BY

Dana Alterman,
RDMS, LVT

HOSPITAL NAME

Eubank Animal Clinic

REFERRING VET

Dr. Bannon

INVOICE

32195

DATE

8/7/23



PATIENT

Kirby Tissot

SPECIES

Canine

BREED

Beagle

SEX

Male Intact

AGE

13.1 years

WEIGHT

32.4lbs

INTERPRETED BY

Maggie Machen Lamy,
DVM, DACVIM
(Cardiology)

IMAGING PERFORMED BY

Dana Alterman,
RDCS, LVT

HOSPITAL NAME

Eubank Animal Clinic

REFERRING VET

Dr. Bannon

INVOICE

32195

DATE

8/7/23

INTERPRETATION OF THE FINDINGS & FURTHER RECOMMENDATIONS

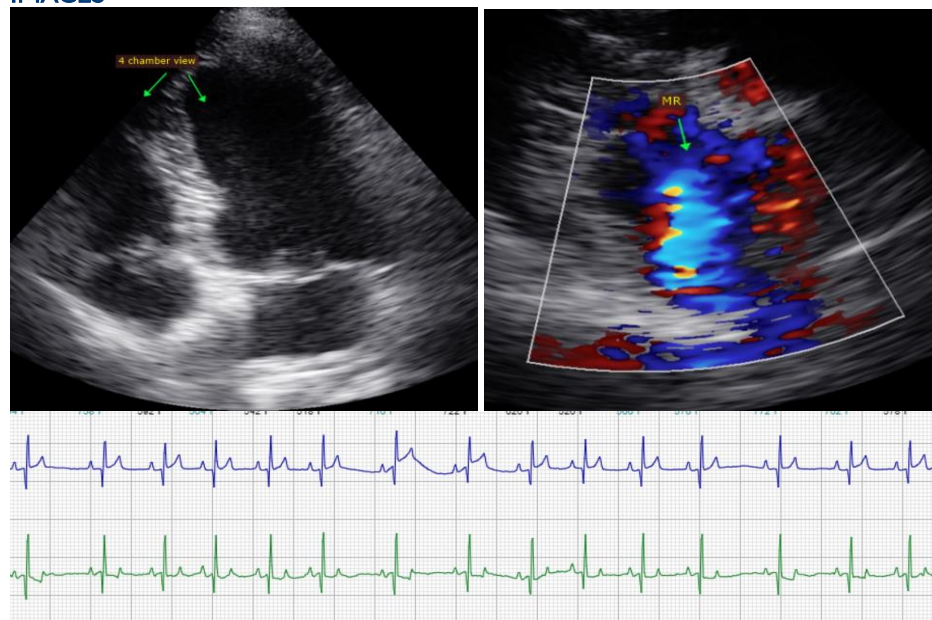
Chronic degenerative valve disease causing mild mitral and trace tricuspid regurgitation. Lack of significant left atrial enlargement indicates the current risk for complication is low. No concurrent issues such as systolic dysfunction or pulmonary hypertension are noted in this study. The ECG is unremarkable with a respiratory sinus arrhythmia.

In a dog with no significant left atrial enlargement, no cardiac medications are clearly indicated. Assessment of progression in the future will help predict long term prognosis, which is highly variable at this stage. Omega fatty acid supplementation and mild salt restriction may be of some long-term benefit. Monitor for development of a cough, labored breathing, exercise intolerance or collapse episodes.

Anesthetic risk is considered mild if needed. Cardiac protective drug choices (opioid/benzodiazepine premedication, propofol or alfaxalone induction, isoflurane gas) are recommended. Pre-oxygenate for 5-10 minutes prior to induction. Monitor for arrhythmias, hypotension, and hypoxia both intra and post-operatively and intervene as necessary. Mild IV fluid restriction is recommended to avoid fluid overload. Avoid heart rate stimulating drugs such as atropine unless clinically indicated.

Recommend conservative monitoring with a recheck echocardiogram in 6 months, sooner if any development of clinical signs.

IMAGES





PATIENT

Kirby Tissot

The information and recommendations provided are based on the images presented by the referring veterinarian. No evaluation can be communicated regarding pathology that was not visible in the image/video clips provided.

SPECIES

Canine

Thank you for this referral. This report was generated using transcription software, and minor dictation errors may be present. If the clinical or image interpretation does not parallel your findings or if I can be of any further assistance, please contact me.

BREED

Beagle

Maggie Machen Lamy, DVM
Diplomate of the American College of Veterinary Internal Medicine (Cardiology)
info@sonopath.com

SEX

Male Intact

AGE

13.1 years

WEIGHT

32.4lbs

INTERPRETED BY

Maggie Machen Lamy,
DVM, DACVIM
(Cardiology)

**IMAGING
PERFORMED BY**

Dana Alterman,
RDCS, LVT

HOSPITAL NAME

Eubank Animal Clinic

REFERRING VET

Dr. Bannon

INVOICE

32195

DATE

8/7/23